

# Evaluation of Retinal Thickness in Neurodegenerative Diseases using Spectral Domain Optical Coherence Tomography

BINDU MADHAVI MANAPRAGADA<sup>1</sup>, SHOBHA G PAI<sup>2</sup>, SUSAN D SOUZA<sup>3</sup>, MADHURIMA K NAYAK<sup>4</sup>

## ABSTRACT

**Introduction:** Neurodegenerative diseases are characterised by axonal lesions throughout the central nervous system, including the eye with changes in macular thickness and Retinal Nerve Fiber Layer (RNFL) on histopathologic evaluation. Optical coherence tomography facilitates retina as a surrogate measure of neurodegenerative disease activity.

**Aim:** To evaluate macular thickness and retinal nerve fiber layer thickness in patients with neurodegenerative diseases using spectral domain optical coherence tomography (SD-OCT).

**Materials and Methods:** An analytical observational case control study was carried out over a period of two years. Cases consisted of patients (n=20) with neurodegenerative disorders and controls were age and sex matched healthy individuals. RNFL thickness was measured using the SD OCT. The visual functions tested included the Best Corrected Visual Acuity (BCVA) and colour vision. Fundus examination was done to look for any gross retinal pathologies. All these tests were carried out for cases and controls once during the study. Statistical data analysis was performed by using Mann-Whitney U tests. SPSS

for windows, version 17.0 was used to do the analysis. p-values smaller than 0.05 were considered significant.

**Results:** The study included 13 cases of central neurodegenerative diseases and 7 cases of peripheral neurodegenerative diseases. Mean duration of disease in cases was 37.85 months with 11 cases having more than 24 months duration and 9 cases having less than 24 months duration.

The mean right eye average (RNFL) thickness in cases was 87.05  $\mu\text{m}$  and that of control was 87.40  $\mu\text{m}$  (p=0.932). The mean left eye average retinal nerve fiber layer thickness in cases was 86.47  $\mu\text{m}$  and control was 89.26  $\mu\text{m}$  (p=0.419).

The mean macular cube average thickness of right eye was 271.05  $\mu\text{m}$  in cases and 270.85  $\mu\text{m}$  in controls. The mean macular cube average thickness of left eye was 266.63  $\mu\text{m}$  in cases and 269.42  $\mu\text{m}$  in controls.

**Conclusion:** Retinal segmentation techniques extend the utility of OCT to neurodegenerative disorders, enabling the in vivo objective assessment of retinal neurons in addition to axonal integrity.

**Keywords:** Central and peripheral neurodegenerative diseases, Optical coherence tomography, Retinal nerve fiber layer

## INTRODUCTION

Neurodegenerative diseases such as multiple sclerosis, Alzheimer's disease, and Parkinson's disease, are characterised by axonal lesions throughout the central nervous system, including the eye [1]. Specifically in multiple sclerosis, histopathologic studies have reported macular thickness changes and RNFL thinning, and these changes have been correlated with disease activity and white matter lesion volume on neuroradiologic studies, such as magnetic resonance imaging [2-5].

The ease of in vivo cross-sectional retinal tissue imaging with Optical Coherence Tomography (OCT) facilitates the use of the retina as a surrogate for neurodegenerative disease activity. Spectral-Domain OCT (SDOCT) is characterised by markedly increased image acquisition speed, improved axial resolution, and true volumetric calculations (much less interpolation), image registration enabling accurate long-term monitoring, and improved image segmentation, facilitating analysis of specific retinal layers. It is being increasingly utilized for evaluation of a variety of ocular diseases, such as glaucoma, age-related macular degeneration, macular hole, epiretinal membrane, and diabetic macular edema. OCT is a non-invasive, non-contact diagnostic tool that provides high-resolution cross-sectional images of the retina [3].

This technique enables, among others, the measurement of the thickness of the RNFL around the optic disc and also the thickness and volume of the macula lutea in vivo. With the use of OCT image processing, not only the thickness of the total retina but also the thickness of the intraretinal layers can be measured

in the macular area. OCT provides high resolution images by using a long wavelength (1,310 nm) of light; it offers rapid and easy quantitative analysis of various structures [3]. This study aimed at evaluation of macular thickness and (RNFL) thickness in patients with neurodegenerative diseases using (SD-OCT). Also, to demonstrate macular and RNFL thickness changes in neurodegenerative diseases other than multiple sclerosis. To compare macular thickness and (RNFL) thickness in patients with central and peripheral neurodegenerative diseases.

## MATERIALS AND METHODS

This study was a case control study with a study period of 2 years (December 2012 to December 2014). All the patients with neurodegenerative diseases attending the neurology outpatient department were included. A universal sampling was done, we received 20 cases and accordingly 20 age and sex matched controls were included. Ethical committee approval was obtained during the conceptualization of the study. Informed consent was obtained from all participants of study after detailed explanation of the procedures involved in the study and the same was documented.

Patients with primary and secondary glaucoma, diabetic retinopathy, hypertensive retinopathy, and other retinal diseases, patients with high refractive errors and patients with history of intraocular surgeries or injury were excluded.

Patients with neurodegenerative conditions were examined for visual acuity, best corrected visual acuity, anterior segment examination, dilated fundus examination, and macular thickness and (RNFL) thickness measured by SD-OCT.

Cirrus HD-OCT (model 4000, rev B, software version 4.0) machine was used. It is a computerized instrument that acquires and analyses cross-sectional and three-dimensional tomograms of the eye using (SD-OCT). SD-OCT is a form of non-invasive, low-coherence interferometry that produces high-resolution tomograms without contacting the eye. All the scans were done by a single person.

Statistical data analysis was done using Mann-Whitney u tests. SPSS version 17.0 was used for analysis. p-value < than 0.05 was considered significant.

## RESULTS

Twenty cases of neurodegenerative disorder and twenty age and sex matched controls were enrolled in the study. The list of various neurodegenerative diseases included in this study in the order of frequency is shown in [Table/Fig-1]. Out of twenty cases, 11 were males and 9 were females in cases and controls. The mean age of cases was 48.85 years and controls was 49.00 years with age distribution as shown below [Table/Fig-2].

Disease	No. of cases
Parkinson's disease	8
Parkinson's plus syndrome	1
Chronic Inflammatory Demyelinating Polyneuropathy (CIDP)	3
Multiple sclerosis	2
Tuberous sclerosis	2
Spinal multiple sclerosis	1
Degenerative motor neuron disease	1
Alzheimer's disease	1
Spinocerebellar ataxia	1

[Table/Fig-1]: Neurodegenerative diseases included in this study.

	Frequency	Percent
<25	3	15.0
26-35	3	15.0
36-45	2	10.0
46-55	4	20.0
>55	8	40.0
Total	20	100.0

[Table/Fig-2]: Age (years) distribution in cases and controls.

The study included 13 cases of central neurodegenerative diseases and 7 cases of peripheral neurodegenerative diseases. Mean duration of disease in cases was 37.85 months with 11 cases having more than 24 months duration and 9 cases having less than 24 months duration.

The mean right eye average (RNFL) thickness in cases was 87.05 μm and that of control was 87.40 μm (p=0.932). The mean left eye average (RNFL) thickness in cases was 86.47 μm and control was 89.26 μm (p=0.419). The mean of (RNFL) thickness in different quadrants of right and left eye listed in [Table/Fig-3]. A p-value in LE temporal quadrant was statistically significant.

	RNFL thickness	Cases (μm)	Controls (μm)	p-value
RE	Superior quadrant	109.00	109.25	0.979
	Temporal quadrant	55.15	59.05	0.273
	Inferior quadrant	116.65	114.25	0.692
	Nasal quadrant	70.25	70.15	0.979
LE	Superior quadrant	107.89	115.79	0.260
	Temporal quadrant	51.26	63.00	0.013
	Inferior quadrant	114.42	117.79	0.503
	Nasal quadrant	69.11	68.89	0.959

[Table/Fig-3]: Mean of RNFL thickness in different quadrants.

\* RNFL- Retinal Nerve Fiber Layer; RE- Right Eye; LE- Left Eye

The mean macular cube average thickness of right eye was 271.05 μm in cases and 270.85 μm in controls. The mean macular cube average thickness of left eye was 266.63 μm in cases and 269.42 μm in controls. The mean of thickness in different areas of macula of right and left eye are listed in [Table/Fig-4].

	Macular thickness	Cases (μm)	Controls (μm)	p-values
RE Perifoveal	Superior	308.80	315.10	0.252
	Temporal	301.00	308.90	0.247
	Inferior	305.40	313.80	0.165
	Nasal	302.55	313.70	0.128
RE Parafoveal	Superior	275.40	275.90	0.924
	Temporal	260.60	263.50	0.752
	Inferior	264.20	266.20	0.694
	Nasal	284.30	281.50	0.662
LE Perifoveal	Superior	302.37	312.58	0.160
	Temporal	283.84	300.89	0.096
	Inferior	295.74	312.47	0.041
	Nasal	299.95	312.47	0.204
LE Parafoveal	Superior	273.63	271.68	0.716
	Temporal	256.16	261.74	0.381
	Inferior	257.68	262.74	0.427
	Nasal	281.53	289.53	0.149

[Table/Fig-4]: Mean thickness in different areas of macula.

\* RE- Right Eye; LE- Left Eye

The mean average retinal nerve fiber thickness and mean average macular cube thickness in various cases listed in [Table/Fig-5]. The p-value is significant for LE.

Variables	Central neurodegenerative diseases	Peripheral neurodegenerative diseases	p-value
Average RNFL thickness of RE	83.54 μm	93.57 μm	0.139
Average RNFL thickness of LE	82.25 μm	93.71 μm	0.046
macular cube Average thickness of RE	270.15 μm	272.71 μm	0.547
macular cube Average thickness of LE	263.58 μm	271.86 μm	0.181

[Table/Fig-5]: Mean average RNFL thickness and macular cube thickness in various cases.

\* RNFL- Retinal Nerve Fiber Layer RE- Right Eye; LE- Left Eye

The mean average retinal nerve fiber thickness and mean average macular cube thickness in cases depending on the duration of disease is listed in [Table/Fig-6].

Variables	Duration of disease <24 months (μm)	Duration of disease >24 months (μm)	p-value
Average RNFL thickness of RE	92.27	80.67	0.070
Average RNFL thickness of LE	88.30	84.44	0.509
Macular cube average thickness of RE	272.36	269.44	0.473
Macular cube average thickness of LE	267.60	265.56	0.739

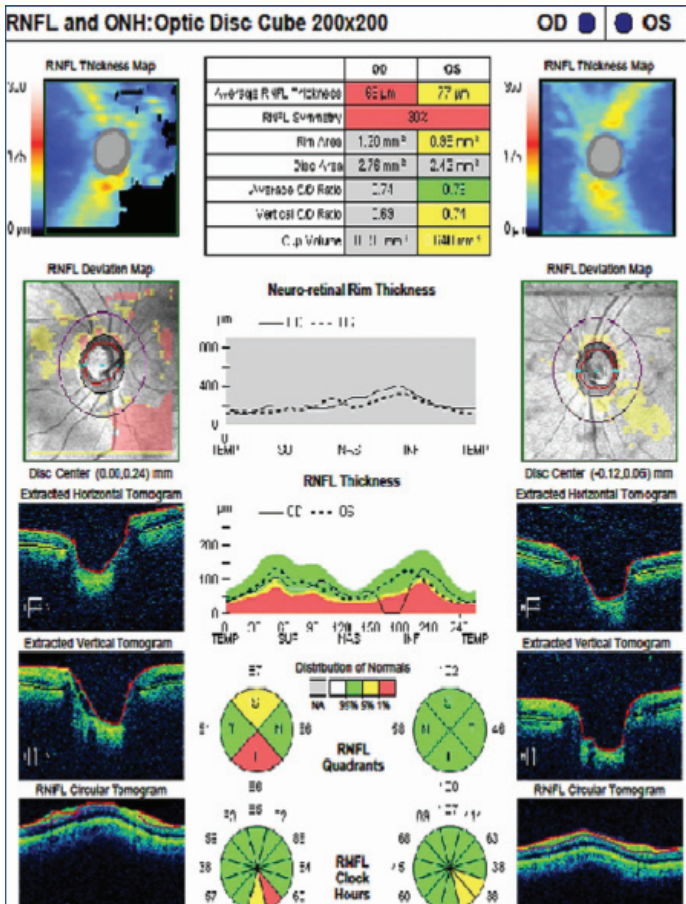
[Table/Fig-6]: Mean average retinal nerve fiber thickness and mean average macular cube thickness.

\* RNFL-Retinal Nerve Fiber Layer; RE- Right Eye; LE-Left Eye

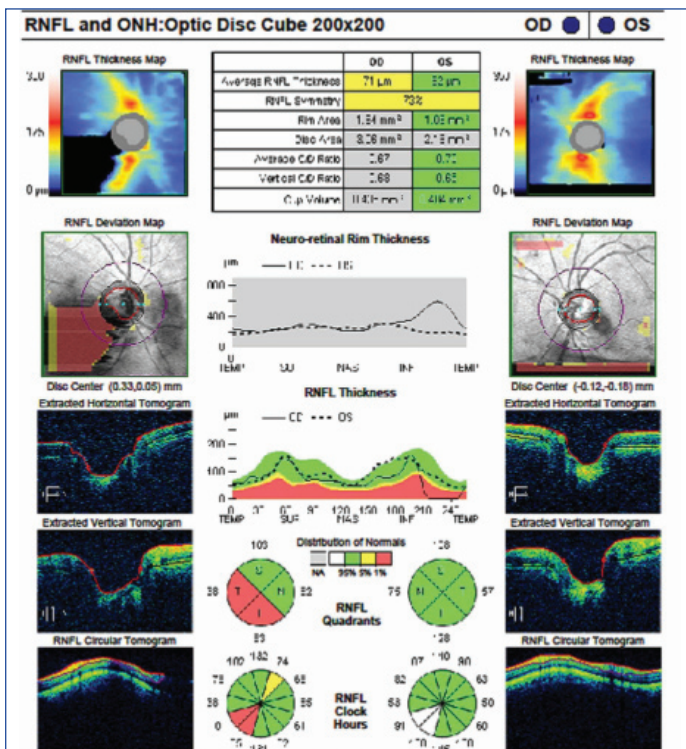
## DISCUSSION

The present study compared SD OCT (RNFL and the macular thickness) findings in different types of neurodegenerative disorders with an age and sex matched control group [Table/Fig-7,8]. We have also compared the SD OCT findings between central and peripheral neurodegenerative disorders and correlated the findings with duration of disorder.

The present study included 20 cases of different central and peripheral neurodegenerative disorders with 9 cases of Parkinson's disease, 3



[Table/Fig-7]: RNFL and optic disc cube of a multiple sclerosis case.



[Table/Fig-8]: RNFL and optic disc cube of an age and sex matched control.

cases of Chronic Inflammatory Demyelinating Polyneuropathy (CIPD), 2 cases each of Multiple sclerosis and Tuberculous sclerosis, and 1 case each of Spinal multiple sclerosis, Degenerative motor neuron disease, Alzheimer's disease, and Spinocerebellar ataxia which were compared to 20 age and sex matched controls.

The average (RNFL) thickness in cases as compared to controls was less but was not statistically significant in both the eyes. RNFL thickness in Temporal quadrant was noted to be more affected in both eyes with p-value = 0.273 in right eye and 0.013 in left eyes

which was not statistically significant, considering p-value <0.05 significant but a significant decrease in visual acuity was noted. Loughran-Fjeldstad AS et al., had identified that the temporal quadrant seems to be a more vulnerable area within the RNFL in Multiple Sclerosis (MS) patients [6], which is in agreement with the findings of Wings KM et al., [7]. The temporal quadrant contains fibers of the peripapillary macular bundle [8,9] which appeared to be a compromised area with clear distinction between the controls and neurodegenerative disease affected groups.

Mean of macular cube average thickness of right and left eye in cases and controls were almost equal. Thus, we found that the macular region was not affected much in neurodegenerative disorders as compared to optic nerve head region. This may be because optic nerve is the direct extension from the central nervous system hence, optic nerve head retinal nerve fiber thickness was more affected in these cases of neurodegenerative disorders which primarily affect the central nervous system.

Average RNFL thickness in cases with central neurodegenerative disorders was less than in cases with peripheral neurodegenerative disorders with RE p-value = 0.139 and LE p-value = 0.046 (statistically significant). The difference between macular cube average thickness in central versus peripheral neurodegenerative disorders was almost equal with p-value = 0.547 in right eye and 0.181 in left eye (which was not statistically significant).

Average RNFL thickness was found to be decreased in cases with more than 24 months duration of neurodegenerative disorders. Cases with duration more than 24 months had thinner average (RNFL) and macular thickness when compared to cases with duration of less than 24 months. Not many studies have been done in this area and further studies might give us better results.

Advantages of SDOCT is that it gives a true volumetric calculation (much less interpolation), image registration enabling accurate long-term monitoring, and improved image segmentation, facilitating analysis of specific retinal layers. RNFL measurement by OCT can possibly quantify the axonal loss taking place in the visual system in Indian eyes in a manner similar to the Caucasian patients and prognosticate visual outcome [10].

In a study, using histopathologic analysis, demonstrated a loss of RNFL thickness in the temporal quadrant in multiple sclerosis-affected eyes [3]. Other investigators utilising SDOCT demonstrated significant RNFL thinning in eyes of patients with multiple sclerosis compared with healthy eyes, but they found differences in all four quadrants in addition to average thickness [11].

Jiménez B et al., demonstrated that eyes of patients with Parkinson Disease (PD) had a statistically significant decrease in average peripapillary RNFL thickness compared with control eyes (p < 0.001). This reduction was observed in every quadrant (inferior, superior, nasal (p<0.001), and temporal (p=0.017)) in patients with PD. This study had found thinning more in the temporal quadrant (but statistically not significant). They had observed that, as the evolution and severity of PD progress, the peripapillary RNFL layer thickness, as evaluated by OCT, gradually diminishes which correlates with the results of our study. These results suggest that the average peripapillary RNFL thickness measured by OCT might be useful as a biomarker to detect the early onset and progression of PD [12].

Further studies have demonstrated that RNFL parameters were significantly reduced in patients with PD, especially when using the Spectralis OCT device. All macular parameters, except for foveal thickness, differed significantly between controls and patients with PD. This study included 153 patients with PD and 242 controls who underwent evaluations of the macula and RNFL using two new-generation Fourier domain OCT devices [13].

In a study by Alvarez G et al., he identified a mild and progressive decrease in RNFL thickness in patients with spino cerebellar ataxia.

A negative correlation exists between an anatomic marker (RNFL thickness) and a clinical severity scale (SARA score); thus, RNFL thickness could be considered as a promising biomarker of the disease [14]. Satue M et al., identified that early damage of the anterior visual pathway occurs in MS, PD, and AD and that the ganglion cell layer is the ultimate biomarker for disease diagnosis, severity, and progression. Thus, OCT technology should be used as a common and very useful clinical complement in the diagnosis and control of neurodegenerative disorders [15].

Few studies have evaluated retinal structure and function in vivo in patients with AD, but the results so far have been controversial [16-25]. One of the major sources of inconsistency in these studies lies in the variability of the techniques used, which vary from ERG [22-24,26,27] to OCT [17,20-25] Scanning Laser Polarimetry (SLP) [18], and Heidelberg Retinal Topograph (HRT) [16]. Another reason for inconsistent results might be because most research has been conducted on the peripapillary area [20-23,25].

## CONCLUSION

This study is limited by the numbers included; probably larger group of patients would widen the probability of statistically significant findings.

In summary, retinal segmentation techniques extend the utility of OCT to neurodegenerative disorders, enabling the in vivo objective assessment of retinal neurons in addition to axonal integrity. This study supports recent findings and may facilitate further understanding of the pathobiological underpinnings of these highly complex and heterogeneous disorders. In this study average RNFL thickness at the optic disc was found to be more affected depending on the duration of the neurodegenerative diseases. Longer the duration of neurodegenerative diseases more the thinning of RNFL was found. Average RNFL and macular thickness in patients with neurodegenerative diseases were less than the age and sex matched control group. RNFL thickness in Temporal quadrant in patients with neurodegenerative diseases was found to be more affected in BE.

## REFERENCES

- [1] Frohman EM, Fujimoto JG, Frohman TC, Calabresi PA, Cutter G, Balcer LJ. Optical coherence tomography: A window into the mechanisms of multiple sclerosis. *Nat Clin Pract Neurol*. 2008;4:664-75.
- [2] Frisén L, Hoyt WF. Insidious atrophy of the retinal nerve fibers in multiple sclerosis. Fundoscopic identification in patients with and without visual complaints. *Arch Ophthalmol*. 1974;92:91-97.
- [3] Kerrison JB, Flynn T, Green WR. Retinal pathologic changes in multiple sclerosis. *Retina*. 1994;14:445-51.
- [4] Gordon-Lipkin E, Chodkowski B, Reich DS, Smith SA, Pulicken M, Balcer LJ, et al. Retinal nerve fiber layer is associated with brain atrophy in multiple sclerosis. *Neurology*. 2007;69:1603-09.
- [5] Grazioli E, Zivadinov R, Weinstock-Guttman B, Lincoff N, Baier M, Wong JR, et al. Retinal nerve fiber layer thickness is associated with brain MRI outcomes in multiple sclerosis. *J Neurol Sci*. 2008;268:12-17.
- [6] Loughran-Fjeldstad AS, Carlson NG, Husebye CD, Cook LJ, Rose JW. Retinal nerve fiber layer sector-specific compromise in relapsing and remitting multiple sclerosis. *E Neurological Sci*. 2015;1:30-37.
- [7] Wings KM, Werner JS, Harvey DJ. Baseline retinal nerve fiber layer thickness and macular volume quantified by OCT in the north American phase 3 fingolimod trial for relapsing-remitting multiple sclerosis. *J Neuro-ophthalmol*. 2013;33(4):322-29. [PubMed]
- [8] Green AJ, McQuaid S, Hauser SL. Ocular pathology in multiple sclerosis: retinal atrophy and inflammation irrespective of disease duration. *Brain*. 2010;133(Pt 6):1591-601. [PubMed]
- [9] Gelfand JM, Goodin DS, Boscardin WJ. Retinal axonal loss begins early in the course of multiple sclerosis and is similar between progressive phenotypes. *PLoS One*. 2012;7(5) [PMC free article] [PubMed]
- [10] Saxena R, Bandyopadhyay G, Singh D, Singh S, Sharma P, Menon V. Evaluation of changes in retinal nerve fiber layer thickness and visual functions in cases of optic neuritis and multiple sclerosis. *IJO*. 2013;61(10):562-66.
- [11] Bock M, Brandt AU, Dörr J, Pfueller CF, Ohlraun S, Zipp F, et al. Time domain and spectral domain optical coherence tomography in multiple sclerosis: A comparative cross-sectional study. *Mult Scler*. 2010;16:893-96.
- [12] Jiménez B, Ascaso FJ, Cristóbal JA, López del Val J. Development of a prediction formula of Parkinson disease severity by optical coherence tomography *MovDisord*. 2014;29(1):68-74.
- [13] Satue M, Seral M, Otin S, Alarcia R, Herrero R, Bambo MP, et al. Retinal thinning and correlation with functional disability in patients with Parkinson's disease. *Br J Ophthalmol*. 2014;98(3):350-55.
- [14] Alvarez G, Rey A, Sanchez-Dalmau FB, Muñoz E, Ríos J, Adán A. Optical coherence tomography findings in spinocerebellar ataxia-3 *Eye (Lond)*. 2013;27(12):1376-81.
- [15] Satue M, Obis J, Rodrigo MJ, Otin S, Fuertes MI, Vilades E, et al. Optical Coherence Tomography as a Biomarker for Diagnosis, Progression, and Prognosis of Neurodegenerative Diseases. *J Ophthalmol*. 2016;2016: 8503859. Published online 2016 Oct 20.
- [16] Iseri PK, Altinas O, Tokay T, Yüksel N. Relationship between cognitive impairment and retinal morphological and visual functional abnormalities in Alzheimer disease. *J Neuroophthalmol*. 2006;26:18-24.
- [17] Kergoat H, Kergoat MJ, Justino L, Chertkow H, Robillard A, Bergman H. An evaluation of the retinal nerve fiber layer thickness by scanning laser polarimetry in individuals with dementia of the Alzheimer type. *Acta Ophthalmol Scand*. 2001;79:187-91.
- [18] Kergoat H, Kergoat MJ, Justino L, Robillard A, Bergman H, Chertkow H. Normal optic nerve head topography in the early stages of dementia of the Alzheimer type. *Dement Geriatr Cogn Disord*. 2001;12:359-63.
- [19] Lu Y, Li Z, Zhang X, Ming B, Jia J, Wang R, et al. Retinal nerve fiber layer structure abnormalities in early Alzheimer's disease: evidence in optical coherence tomography. *Neurosci Lett*. 2010;480:69-72.
- [20] Paquet C, Boissonnot M, Roger F, Dighiero P, Gil R, Hugon J. Abnormal retinal thickness in patients with mild cognitive impairment and Alzheimer's disease. *Neurosci Lett*. 2007;420:97-99.
- [21] Parisi V. Correlation between morphological and functional retinal impairment in patients affected by ocular hypertension, glaucoma, demyelinating optic neuritis and Alzheimer's disease. *Semin Ophthalmol*. 2003;18:50-57.
- [22] Parisi V, Restuccia R, Fattapposta F, Mina C, Bucci MG, Pierelli F. Morphological and functional retinal impairment in Alzheimer's disease patients. *Clin Neurophysiol*. 2001;112:1860-67.
- [23] Trick GL, Barris MC, Bickler-Bluth M. Abnormal pattern electroretinograms in patients with senile dementia of the Alzheimer type. *Ann Neurol*. 1989;26:226-31.
- [24] Valenti DA. Neuroimaging of retinal nerve fiber layer in AD using optical coherence tomography. *Neurology*. 2007;69:1060.
- [25] Justino L, Kergoat M, Bergman H, Chertkow H, Robillard A, Kergoat H. Neuroretinal function is normal in early dementia of the Alzheimer type. *Neurobiol Aging*. 2001;22:691-95.
- [26] Katz B, Rimmer S, Iragui V, Katzman R. Abnormal pattern electroretinogram in Alzheimer's disease: evidence for retinal ganglion cell degeneration? *Ann Neurol*. 1989;26:221-25.
- [27] Krasodomska K, Lubinski W, Potemkowski A, Honczarenko K. Pattern electroretinogram (PERG) and pattern visual evoked potential (PVEP) in the early stages of Alzheimer's disease. *Doc Ophthalmol*. 2010;121:111-21.

### PARTICULARS OF CONTRIBUTORS:

1. Resident, Department of Ophthalmology, Kasturba Medical College and Hospital, Manipal University, Mangalore, Karnataka, India.
2. Additional Professor, Department of Ophthalmology, Kasturba Medical College and Hospital, Manipal University, Mangalore, Karnataka, India.
3. Senior Resident, Department of Ophthalmology, Kasturba Medical College and Hospital, Manipal University, Mangalore, Karnataka, India.
4. Senior Resident, Department of Ophthalmology, Kasturba Medical College and Hospital, Manipal University, Mangalore, Karnataka, India.

### NAME, ADDRESS, E-MAIL ID OF THE CORRESPONDING AUTHOR:

Dr. Bindu Madhavi Manapragada,  
Flat No. 204, Sri Sai Muraliapt, Kothapet Village, Mohan Nagar, Hyderabad-500035, Telangana, India.  
E-mail: bindu\_manapragada@yahoo.com

Date of Submission: **Jan 21, 2018**  
Date of Peer Review: **Mar 11, 2018**  
Date of Acceptance: **May 28, 2018**  
Date of Publishing: **Aug 01, 2018**

FINANCIAL OR OTHER COMPETING INTERESTS: None.